

Illinois State University

ISU ReD: Research and eData

Theses and Dissertations

3-9-2017

The Therapeutic Effects Of Dry Cupping On Iliotibial Band Tightness

Madeline Marie Biehl

Illinois State University, mmbiehl@ilstu.edu

Follow this and additional works at: <https://ir.library.illinoisstate.edu/etd>



Part of the [Kinesiology Commons](#)

Recommended Citation

Biehl, Madeline Marie, "The Therapeutic Effects Of Dry Cupping On Iliotibial Band Tightness" (2017). *Theses and Dissertations*. 728.

<https://ir.library.illinoisstate.edu/etd/728>

This Thesis is brought to you for free and open access by ISU ReD: Research and eData. It has been accepted for inclusion in Theses and Dissertations by an authorized administrator of ISU ReD: Research and eData. For more information, please contact ISUREd@ilstu.edu.

THE THERAPEUTIC EFFECTS OF DRY CUPPING ON ILIOTIBIAL BAND TIGHTNESS

Madeline Marie Biehl

29 Pages

Context: The iliotibial band (ITB) is a muscle-like structure on the outside of the thigh and plays a vital role in movement and can become tight if overused. This tightness can lead to a wide array of injuries in an otherwise healthy individual. Previous research has proved the need to treat a tight ITB, but techniques previously researched have not proven to be effective in reducing ITB tightness. Dry cupping is a method in which suction is generated from a vacuum-sealed cup using a pump in order to alleviate pain, reduce tightness, and promote healing. Recently, cupping has been used as a therapeutic treatment to relieve muscular tightness. Currently, there is no research on the effectiveness of dry cupping in relieving lower extremity tightness, particularly ITB tightness

Objective: To determine if dry cupping is an effective treatment intervention in releasing ITB tightness and increasing hip and knee range of motion in a physically active population.

Design: Controlled laboratory study with randomization and clinician and participant blindness.

Setting: Athletic Training Laboratory

Patients or Other Participants: Forty healthy participants (17 males, 23 females; age: 21 ± 1.8 years; height: 170.94 ± 10.81 cm; weight: 74.20 ± 13.67 kg) with ITB tightness as determined by a positive Ober's test (-12.79 ± 6.86 degrees). Participants were excluded if there was current pain and/or injury to the leg in the past year, had an intervention for ITB tightness in the past

three months, blood flow dysfunctions, hemorrhagic disorders, cancer, or a possibility of pregnancy.

Intervention(s): Dry cupping or sham cupping. Participants were placed in a side-lying position with pillow between slightly bent knees. Four stationary cups were placed along the ITB for seven minutes. Cup placement was determined based off a scanning technique used to identify areas with adhesions.

Main Outcome Measure(s): Angle of hip adduction achieved during Ober's test, active and passive hip flexion, and active and passive knee flexion.

Results: There were no significant differences between groups for any measure ($p > .305$). However, after running effect sizes between groups for immediate post and 24 hours after intervention, some variables had strong effects, namely Ober's (immediate post: $-.66 (-1.3- -.03)$; 24-hours post: $-.67 (-1.3- -.03)$) and active and passive hip flexion (active 24-hours post: $.67 (.03- 1.3)$; passive 24-hours post: $.66 (.02- 1.29)$).

Conclusions: Our findings indicate that a single intervention of dry cupping is probably effective in reducing ITB tightness and increasing hip flexion ranges of motion. These changes can be observed 24 hours post intervention in addition to immediately after the intervention. This study supports the assumption that dry cupping may be a safe and effective treatment option to combat ITB tightness seen by clinicians.

KEYWORDS: ober's test; hip flexion; knee flexion; cupping

THE THERAPEUTIC EFFECTS OF DRY CUPPING ON ILIOTIBIAL BAND TIGHTNESS

MADLINE MARIE BIEHL

A Thesis Submitted in Partial
Fulfillment of the Requirements
for the Degree of

MASTER OF SCIENCE

School of Kinesiology and Recreation

ILLINOIS STATE UNIVERSITY

2017

© 2017 Madeline Marie Biehl

THE THERAPEUTIC EFFECTS OF DRY CUPPING ON ILIOTIBIAL BAND TIGHTNESS

MADÉLINE MARIE BIEHL

COMMITTEE MEMBERS:

Noelle M. Selkow, Chair

Rebecca Begalle

ACKNOWLEDGMENTS

I would like to acknowledge those who peaked my interest in athletic training and manual therapy specifically. Without them I would not be where I am today. I would also like to thank my family and friends for being the most supportive, both through life and through this process. Their constant words of encouragement fueled me to reach my goal. I also want to express thanks to my thesis committee for supporting me through the thesis process and allowing me to produce this work. Most of all, I would like to thank Paddy Hardy for being the best research assistant I could ask for. Paddy, you know I could not have done this without you; thanks for getting us through all the late nights and early mornings.

M. M. B.

CONTENTS

	Page
ACKNOWLEDGMENTS	i
CONTENTS	ii
TABLES	iv
FIGURES	v
CHAPTER I: INTRODUCTION	1
CHAPTER II: REVIEW OF LITERATURE	3
Anatomy	3
Skin	3
Bone/Joint	4
Muscle	5
Fascia	6
Bursa	8
ITB Tightness	9
Causes	9
Injury Risk	9
Inflammatory Process	10
Ober's Test	10
Treatment Difficulties	11
Manual Therapy	11
Theories of Manual Therapy	11
Benefits of Manual Therapy	13

Potential Side Effects and Contraindications of Manual Therapy	13
Cupping	13
Background/History of Cupping	13
Benefits of Cupping	14
Theories of Cupping	14
Potential Side Effects and Contraindications of Cupping	15
CHAPTER III: METHODS	16
Study Design	16
Participants	16
Instrumentation	16
Procedures	17
Data Reduction	21
Statistical Analysis	21
CHAPTER IV: RESULTS	22
CHAPTER V: DISCUSSION	24
REFERENCES	28

TABLES

Table	Page
1. Descriptive statistics on Ober's test	22
2. Descriptive statistics on hip flexion ranges of motion	22
3. Descriptive statistics on knee flexion ranges of motion	23

FIGURES

Figure	Page
1. Ober's test	18
2. Knee Flexion PROM	19
3. Hip Flexion PROM	19

CHAPTER I: INTRODUCTION

The iliotibial band (ITB) is an anatomical structure composed of nonelastic, collagen fascia on the lateral aspect of the upper leg.¹ Fascia can be defined as a mass of dense connective tissue surrounding muscles, nerves, and blood vessels.² The fascial fibers of the ITB, beginning at the iliac crest and ending at the lateral patella, fibular head, and Gerdy's tubercle, are interwoven with collagen, ground substance, and nerve fibers.^{1,3} These substances within fascia play a role in the cause of tightness. Excessive fibroblast formation can lead to a lack of mobility of the fascia.⁴ Moreover, the collagen within fascia can contain cross links and form adhesions in the ITB causing tightness of the structure.⁴

The ITB has both a passive and dynamic role at the patellofemoral and hip joints.^{1,5} The ITB provides stability by increasing tension and altering loading mechanics at these two joints.^{6,7} Due to its origin and insertion, the ITB plays a vital role in movement, specifically during the stance and swing phase of running mechanics.¹ During these motions, the ITB allows for fluid movements and maintains proper biomechanics.^{1,7} The ITB acts as a synergist to the muscles involved in hip and knee flexion.⁷ Therefore, a tight ITB may alter biomechanics and increase the risk of injury.⁸ For example, tightness at the patellar insertion of the ITB may lead to a lateral tracking patella, resulting in patellofemoral dysfunction or ITB friction syndrome.^{6,7,9} Additionally, since the ITB acts as a restraint to anterior tibial translation, tightness may result in an anterior pull of the tibia,⁷ increasing the risk for anterior cruciate ligament injuries.^{5,10-12}

ITB tightness is a common ailment among athletes and is especially common in long distance sports such as running and cycling¹² from repetitive hip and knee flexion and extension. Ober's test is the accepted method by clinicians to determine if ITB tightness is present. Ferber et al.¹³ established normative data for Ober's test and range of motion (ROM) for the ITB.

During the test, the leg would need to drop 23.16° or less from the horizontal starting position to be positive for tightness.¹³

Since fascial tightness is difficult to treat due to the tissue being non-contractile, several forms of instrument assisted techniques have been developed to combat this tightness, including cupping therapy. Dry cupping is a method in which suction is generated from a vacuum-sealed cup using a pump.¹⁴⁻¹⁹ The purpose of creating this suction is to promote blood flow to the area. The blood circulating in the treatment area is theorized to alleviate pain and promote healing.¹⁵⁻²⁰ Recently, cupping has been used as a therapeutic treatment to relieve muscular tightness,^{14,15,19} however, there are no known mechanisms for how cupping may relieve fascial tightness. One explanation is that the mechanism is similar to other manual therapies in that the layers of fascia and muscle separate to reduce adhesions.³ There have been no studies performed on dry cupping in relation to ITB tightness.

Therefore, the purpose of this study is to determine if dry cupping is an effective treatment option in releasing ITB tightness and increasing ROM in a healthy population that present with a positive Ober's test. We hypothesize that cupping will be effective in reducing ITB tightness and increasing ROM compared to sham cupping.

CHAPTER II: REVIEW OF LITERATURE

Anatomy

Skin

Skin is one of the most versatile organs in the body and is vital in maintaining homeostasis in the body.² The skin is composed of two primary layers, the epidermis and dermis, There is also the hypodermis that provides some of the protective functions of skin.²

The epidermis is the outermost layer of the body and is characterized as keratinized stratified squamous epithelium.² The main purpose of the epidermis is to be a protective shield for the underlying tissues. Within the epidermis are cells that allow for sensation, protection, and pigmentation.² Nutrients reach the epidermis by diffusing through the blood vessels of the dermal layer of skin.²

The dermis is the second layer of skin and lies just deep to the epidermis. The dermis is the only layer of skin that is vascularized.² The dermis makes up the bulk of the skin, as it is comprised mostly of dense, irregular connective tissue. The dermis has a rich supply of blood vessels, nerve fibers, and lymphatic vessels.² The nerve fibers carry motor impulses to the dermal muscles and sensory impulses away from the sensory receptors.² Cutaneous receptors, glands, and hair follicles also reside within the dermis. The deepest layer of skin is the hypodermis.²

The hypodermis, also known as the subcutaneous layer of skin, lies deep to the dermis.² This layer is superficial to the fascia of the skeletal muscles and is composed mostly of adipose. This fatty composition allows the skin to act as both a shock absorber and an insulator reducing the amount of heat lost from the body.² The hypodermis also anchors the skin to the underlying

muscle and structures. This attachment is loose enough to allow sliding of the skin, which serves a protective mechanism from blows taken by the body.²

Bone/Joint

The hip joint is the articulation of the pelvis and the femur. The femoral head sits in the acetabulum of the pelvis to create stability at this joint.² The femoral head is held in the acetabulum with the help of the ligamentum teres, which prevents inferior translation of the femur.² Other surrounding hip ligaments help to stabilize the hip joint, as does the acetabular labrum.² The femur is the single bone of the thigh. Along the shaft of the femur is the linea aspera in which the ITB attaches to.^{7,9} At the distal portion of the femur are two bony protrusions called epicondyles.² The lateral epicondyle acts as an insertion point for the ITB.^{7,9} Just distal to the epicondyles, the femoral condyles form a groove for the patella to articulate with.² The patella is a sesamoid bone that allows for normal biomechanics at the knee.

The knee joint is formed by the distal femur, the patella, and the tibia.² The ITB crosses this joint to create additional stability.^{6,7,9} The ITB spans across the lateral aspect of the patella and morphs with the lateral retinaculum to attach to the patella.^{7,9} The proximal tibia articulates with the condyles of the femur to create the knee joint.² Along the anterolateral surface of the tibia is a bony prominence called Gerdy's tubercle just distal to the lateral condyle of the tibia.^{7,9} This tubercle is a primary attachment site for the ITB.^{6,7,9} The wide insertion of this attachment site encompasses the head of the fibula where it articulates with the tibia.^{2,6} Though some stability of the knee joint comes from bony congruency, a large portion of stability is due to the menisci and ligaments within the joint.² The lateral patellar retinaculum and the patellar ligament merge in conjunction with the ITB along the lateral patella and tibia to provide additional support and restraint of lateral patellar movement.² The anterior cruciate ligament (ACL) is an

intra-capsular ligament that runs from the posteromedial aspect of the lateral femoral condyle to the anterior intercondylar aspect of the tibia.² The ACL is an important knee stabilizer as it prevents anterior translation of the tibia and hyperextension of the knee.²

Muscle

Due to both the size and the number of attachment sites of the ITB, a lot of muscles have a relationship with the ITB. The ITB joins the gluteus maximus and tensor fasciae lata (TFL) just distal to the greater trochanter of the femur.^{6,7,9} The ITB articulates with the vastus lateralis and the short head of the biceps femoris as well.^{2,7} In the lower leg, the ITB is associated with the tibialis anterior, peroneus longus, and the extensor digitorum longus.²

The gluteus maximus originates on the posterior third of the ilium and attaches to the femur and ITB posteriorly, and to the greater trochanter laterally.⁶ The inferior gluteal nerve innervates this large muscle. The blood supply is from the superior and inferior gluteal arteries and the first penetrating branch of the profundus femoris artery.⁶ The gluteus maximus is a strong hip joint extensor.⁶

The TFL originates along the iliac crest and inserts onto the ITB. The nerve supply of the TFL is from the superior gluteal nerve.⁶ The TFL's blood supply comes from an ascending branch of the lateral femoral circumflex artery.⁶ The anterior fibers of the TFL flex the hip, while the posterior fibers abduct and internally rotate the hip.⁶ While the TFL produces many movements at the hip, there is relatively low force production in these movements.⁶

The vastus lateralis, which forms the lateral aspect of the thigh, originates at the linea aspera, intertrochanteric line, and the greater trochanter of the femur and inserts on the patella and tibial tuberosity via the patellar ligament.² The femoral nerve and artery supply the nerve and

bloody supply of this muscle.² The actions of the vastus lateralis are to stabilize the leg and extend the knee.²

The biceps femoris is the most lateral muscle of the hamstring group and separates into two heads, the long head and the short head.² The short head of the biceps femoris has similar origins and insertions of the ITB. The short head originates at the linea aspera, lateral supracondylar line, and the distal femur and inserts on the lateral condyle of the tibia and the head of the fibula.² The common fibular nerve and sciatic nerve innervate this muscle.² The main actions of the biceps femoris are hip extension and knee flexion.²

The tibialis anterior is located on the lateral aspect of the lower leg. This muscle originates at the lateral condyle and upper two thirds of the tibia and inserts on the medial cuneiform and metatarsal.² The deep fibular nerve innervates the tibialis anterior.² The tibialis anterior primarily performs dorsiflexion and also assists in foot inversion.²

The peroneus longus runs along the lateral aspect of the lower leg, originating at the head of the fibula and inserting on the inferior aspect of the first metatarsal and medial cuneiform.² The superficial fibular nerve innervates this muscle.² The peroneus longus performs both plantar flexion and eversion of the foot.²

The extensor digitorum longus is just lateral to the tibialis anterior.² The extensor digitorum longus originates on the lateral condyle of the tibia and inserts at the middle and distal phalanges on toes two through five.² The extensor digitorum longus is innervated by the deep fibular nerve and performs toe extension as well as assisting with dorsiflexion of the foot.²

Fascia

Fascia can be defined as a mass of dense connective tissue surrounding muscles, nerves, and blood vessels.² The three main components of connective tissues are ground substance,

fibers, and cells.² Ground substance consists of fluid that fills the space between fibers and cells. This fluid acts as a medium for diffusion between cells and makes the whole connective tissue more pliable.² The fibers in connective tissue are made up of collagen fibers, elastic fibers, and reticular fibers. In fascia, the collagen fibers provide tensile strength and the elastic fibers provide the tissue with its stretch and recoil function.² The connective tissue cells within fascia are: fibroblasts/fibrocytes, fat cells, white blood cells, mast cells, and macrophages. Fibroblasts are an immature form of fibrocytes; in this form fibroblasts secrete ground substance and fibers of the tissue matrix.² Once in the mature form of the cell, fibrocytes maintain matrix health.² Upon tissue injury, fibrocytes can revert back to fibroblasts to help repair and regenerate the matrix.² Fascia has an interwoven fiber arrangement to allow for the functions of fascia.²¹ The ITB is a fascia directly stemming from skeletal muscle fibers. As one of the densest tissue bands in the entire body, the ITB can be separated into different layers of fascia.²¹

The superficial layer of the ITB consists of the aponeuroses of the vastus lateralis and the biceps femoris muscles and the superficial oblique retinaculum, consisting of the fascial fibers covering the patella and patellar tendon.⁷ Anteriorly, the superficial layer is formed by the patella and lateral patellar ligament.⁷ The posterior border of this layer comes to meet the biceps muscle of the leg.⁷ This layer of the ITB fascia has a wide insertion over Gerdy's tubercle.^{6,7,9} When the superficial layer is dissected and flapped away, the deep layer of the ITB can be seen.⁷ This layer spans from the linea aspera of the femur to the patella and Gerdy's tubercle, where it fuses itself to the superficial layer of the ITB.⁷ The capsular-osseous layer of the ITB originates at the lateral epicondyle and inserts on Gerdy's tubercle.⁷ This layer of the ITB has fibers that extend to the patella and form the lateral femoropatellar ligament.⁷ All three layers of the ITB act together to perform the functions of the ITB.

The ITB acts as a stabilizer, restraint, and a synergist for the surrounding structures.^{1,6,7,9} At both the hip and knee, the ITB stabilizes the joint and acts as a restraint for abnormal motion. The added pressure as the ITB tenses acts as a centralizing force to stabilize the hip joint and reduce the load placed on the hip.⁶ The distal portion of the ITB acts as a restraint to lateral patellar movement, stabilizing that joint.^{7,9} The stabilizing of these two joints is an important factor for proper biomechanics during the stance phase of gait.¹ The ITB also acts as a synergist for the surrounding musculature to allow for fluid movement during both the swing phase of motion.^{1,7} As the swing phase is initiated the ITB tenses throughout to assist in both hip and knee flexion.^{1,7} In addition to acting as a synergist for surrounding musculature, the ITB also acts as a synergist for the ACL.^{7,9} The tension created from the ITB during knee flexion pulls at the tibial insertion in turn pulling the tibia more posteriorly, reducing the amount of anterior tibial translation.^{7,9}

Bursa

A bursa is a synovial fluid filled sac that reduces frictions during movement.² ITB tightness can cause irritation at the greater trochanteric bursa and the bursa between the distal ITB and the lateral femoral epicondyle.²² The trochanteric bursa allows for fluid motion of the gluteus maximus passing over the greater trochanter.²² The bursa near the lateral femoral epicondyle is not considered a primary bursa, but instead a continuation of the capsule of the knee.²² The bursa here lubricates where the ITB passes over the lateral femoral condyle.²² This bursa can become inflamed secondary to overuse of the ITB.²²

ITB Tightness

Causes

Tightness of the ITB often occurs over a length of time due to repeated stress placed on the structure.¹ The fascia of the ITB tightens and creates fascial adhesions leading to ITB tightness. These adhesions can form in a number of ways. If the inflammation process is initiated in a region of the ITB, the enhanced hydration of the matrix from the vasodilation may lead to stiffening of the dense connective tissue and harden the fascia, creating an adhesion in that location and restricting range of motion.²³ During the inflammatory response, excessive fibroblast formation can lead to decreased mobility of a fascia.⁴ Adhesions also form when cross links are created in fascia. Cross links form whenever there is a change in the collagen formation of the fascia.⁴

Injury risk

ITB tightness is commonly found in athletes with repetitive hip and knee flexion and knee extension, such as long distance runners and cyclists.^{1,12} When existing fascial adhesions lead to an overall tightness and range of motion restrictions, pulling or overcrowding of the ITB fibers can occur and lead to altered biomechanics which increase the risk of injury.²⁴ Due to the lateral patellar insertion, ITB tightness can result in a lateral pull of the patella (Genu varum) leading to patellofemoral dysfunction and ITB friction syndrome.^{6,7,9,22} ITB tightness can also cause an anterior pull on the tibia, at the ITB attachment site, and increase the risk of ACL injuries.^{5,10-12} Tightness of the ITB limits passive adduction of the affected limb potentially altering biomechanics in the swing phase of gait.⁶

Inflammatory Process

Inflammation is the body's response to an abnormal mechanical stress or injury. The inflammatory process has three main phases: inflammation phase, regeneration and repair phase, and remodeling phase.² Upon trauma, inflammatory chemicals are released causing capillaries in and around the area to dilate and increase vascular permeability.² The vasodilation aspect of the inflammatory phase allows for more oxygen to travel to the injury site and aid in the healing process.² The excess permeability also allows for healing substances, such as white blood cells and clotting proteins, to enter the tissue and begin forming a blood clot.²

During the regeneration and repair phase the blood clot begins to be replaced with new tissue.² This new tissue has a high amount of capillaries which allows for more nutrition and oxygen to come to the injured tissue area.² The new collagen being laid down is created by fibroblasts within the tissue.² Typically, this tissue repair is messy and causes scar tissue to form which can contribute to tightness of the tissue.² The collagen fibers of the new tissue can remodel for up to a year after the initial injury. This remodeling phase is when the collagen fibers shorten to create a tight scar and restore the function of the tissue.² The remodeling of the collagen also improves the tensile strength of the tissue.²

Ober's Test

Ober's test is an accepted special test used to assess ITB tightness. The test is performed with the subject lying on their non-affected limb side.^{10,13} The testing position is in a side lying position with the pelvis and shoulders aligned along a vertical plane and the knee flexed to 90 degrees.^{10,13} A clinician stabilizes the pelvis with one hand while the other hand moves the tested limb into hip flexion, abduction, and extension and then lowers the limb into adduction until the descending limb stops due to either soft tissue restriction or a posterior rotation of the pelvis.^{10,13}

A positive Ober's test is when the descending leg remains in an abducted position while the correlating muscles are relaxed.^{10,13} A positive test is indicative of ITB tightness.^{10,13}

Ferber et al.¹³ has established critical criteria to determine the exact amount of leg adduction to dictate a positive Ober's test. During the test, the affected limb would need to drop 23.16° or less from the starting position to be considered a positive test.¹³ This exact degree was established by including 1 standard deviation both above and below the mean of the limbs that tested positive.¹³ A 1.56° overlap was used to include those whose degree fell within the overlap between positive and negative Ober test.¹³

Treatment Difficulties

The anatomy and physiology of the ITB suggests that it is not a structure that can be stretched.^{9,25,26} Because of both the attachments and the length of the ITB, physiological lengthening of the fascia is limited.²⁶ Since fascia is a non-contractile tissue, tightness is difficult to treat, especially in a thick fascia like the ITB.²⁷ Previous studies conducted on stretching the ITB have revealed that the fascial aspect of the ITB itself does not lengthen, but rather the surrounding musculature.²⁶ This has been theorized to be due to the large amount of collagen components versus elasticity of fascia.^{2,26,27} Stretching does not produce enough mechanical stress on the fascia to cause actual deformation and elongation of the tissue.^{26,27} Therefore, other therapies need to be introduced to address and treat ITB tightness.

Manual Therapy

Theories of Manual Therapy

Manual therapy is a physical treatment intervention for musculoskeletal dysfunction and/or pain applied by a clinician, often involving the use of the hands. In addition, instrumented assisted intervention methods may also be incorporated to target deeper tissues. There are two

main indications for the use of manual therapy: pain and restricted range of motion.³ There are different theories explaining how manual therapy attains these goals.

One accepted theory of manual therapy is the disruption of crosslinks to break up adhesions formed in fascia.^{3,28} It is theorized that manual therapy loosens the crosslinks formed in adhesions and elongates the tissue treated.²⁸ The breaking of crosslinks initiates the inflammatory response and restores interstitial fluid levels.^{3,23,28} The use of an instrument in manual therapy techniques is to purposefully initiate the inflammatory response through direct tissue damage.³ The goals of doing so are to speed the healing process and lead to normal frictional resistance of fascia and mobilize the connective tissue.^{3,28} This mobilization allows for an increased sliding of the fascial layers to restore range of motion deficits.⁴

Another theory behind the effectiveness of manual therapy is eliciting a neurophysiological response in the body.^{23,29,30} The provocation manual therapy creates is theorized to activate the central and autonomic nervous systems through mechanoreceptor stimulation. Upon mechanoreceptor activation, vasodilation occurs and alters local blood supply, which in turn changes the tonus of motor units.^{23,30} This change in tonus and blood supply is thought to relax the surrounding tissue and release the fascial adhesion.^{23,29,30}

An additional theory that attempts to explain the cause of the positive effects manual therapy creates is the piezoelectric effect.^{23,24} Manual therapy is believed to increase the amount of ground substance and fibroblasts that makeup fascia.²³ The piezoelectric effect is the idea of adapting the amount of ground substance through a mechanical force, one that is produced when performing manual therapy.²⁴ This alteration is possible do to the change of a mechanical stress to an electrical energy, eliciting ground substance alteration and elongating taut tissue to relieve tightness.²⁴

Benefits of Manual Therapy

Manual therapy has been shown to have positive effects on musculoskeletal injuries and tightness. The primary benefits of manual therapy are reducing pain and increasing range of motion.²⁹ Manual therapy can also be beneficial by improving circulation, inducing relaxation of tissues, breaking apart adhesions, and releasing muscle spasms.²⁹ These benefits come about through the theories and mechanisms mentioned previously.

Potential Side Effects and Contraindications of Manual Therapy

As with any treatment intervention, manual therapy has the possibility for side effects and cases in which the therapy should not be utilized. Recorded side effects of manual therapy include mild soreness in the area treated and possible light-headedness if doing an aggressive treatment.³¹ Contraindications of manual therapy include open wounds, sutures, hematomas, infections, anticoagulant therapies, advanced diabetes, skin hypersensitivity, aneurisms, osteomyelitis, and any circulatory conditions.³¹

Cupping

Background/History of Cupping

The origins of cupping therapy are thought to have been in Ancient China. Cupping therapy has been dated back to 3000 B.C.E with the earliest recorded treatment of cupping in 1500 B.C.E in Egypt.^{17,32} Since then, cupping has been widely utilized in Eastern cultures for a wide array of medical ailments.^{14,17} Traditionally, cupping was thought of healing in an Eastern manner of correcting the flow of Qi in the body.^{14,20,33}

The two manners in which cupping can be performed are known as dry cupping and wet cupping. Dry cupping involves placing a cup, traditionally made of glass, but more commonly plastic, on the skin and suctioning the air from within the cup. This can be done using heat or a

safer method of a suction pump. Wet cupping is the same process but involves blood letting prior to placing the cup on the body.^{34,35} The suction created is strong enough to separate and lift the skin and fascia from the muscle beneath. Research in this area does not reveal a standardized approach for treatment guidelines (ie number of treatment sessions, time between treatment sessions, etc.) for dry cupping. Recently, Western cultures have been interested in the healing abilities of cupping therapy and studies have shown the positive effects dry cupping can have on musculoskeletal injuries.^{14-20,33,36}

Benefits of Cupping

Research on cupping has brought three primary benefits to light: decreases in pain disability/health questionnaire scores, decreases in pain levels, and increases in range of motion (ROM).¹⁵⁻¹⁹ Numerous studies using cupping as an intervention for tight musculature have found that the intervention leads to a decrease in both disability questionnaires and general health questionnaires.¹⁵⁻¹⁹ The participants' scores on the pain scales post cupping intervention were significantly lower than those in control groups.¹⁵⁻¹⁹ These decreases in pain levels were seen as soon as 24 hours^{15,18} and lasted as long as 12 weeks.¹⁷ ROM was used as an outcome measurement in two of the studies. In each study, ROM in the respective body part (cervical motions and lumbar spine motions) increased in the cupping intervention group of the study.^{15,19}

Theories of Cupping

There is no proven physiological mechanism for the effectiveness of cupping. One commonly inferred theory of cupping is the result of increasing blood flow to an area assisting in the healing process.^{15-18,20,36} The tensile stress created from the suctioning of the skin is thought to be enough to rupture blood vessels and increase bloodflow.³³ Another proposed theory states that cupping has a similar mechanism to that of acupuncture in which the nervous system is

activated.²⁰ Like acupressure, cupping is thought to release chemical transmitters to block pain messages and activate the gate control theory of pain. This is theorized to occur from the vasoconstriction/dilation occurring under the cup surface.²⁰

Potential Side Effects and Contraindications of Cupping

As with any form of therapy, cupping has the potential for side effects. To date, the only reported side effects from a properly conducted cupping session have been ecchymosis, edema, and erythema.¹⁵⁻¹⁹ These effects lasted anywhere from several days to several weeks depending on the individual body's response of the patient.²⁰ For this reason cupping is considered a safe treatment with minimal side effects.^{19,20} These side effects that have been reported are a direct result of the mechanism of cupping.³³

There are instances in which cupping should not be used as a viable treatment on a patient. As outlined in previous studies cupping should not be performed if a patient has cancer, a hemorrhagic disorder, blood flow dysfunctions, or the possibility of pregnancy.^{15-17,19,20}

CHAPTER III: METHODS

Study Design

The design of this study was a controlled laboratory study with randomization and clinician and participant blindness. The primary investigator was blinded to all measurement outcomes taken and the participant was blinded to the intervention. The independent variables were the intervention condition (dry cupping or sham cupping) and time (pre, immediate post, and 24 hours post intervention). The dependent variables were the angle of hip adduction achieved during Ober's test, active and passive hip flexion, and active and passive knee flexion.

Participants

Participants were recruited through classes and flyers posted throughout a Division I campus. A healthy population of 40 participants (17 males, 23 females; Age: 21 ± 1.8 years; Height: 170.94 ± 10.81 cm; Weight: 74.20 ± 13.67 kg), with ITB tightness as determined by a positive Ober's test (-12.79 ± 6.86 degrees), was used for this study. The participant was excluded if there was current pain and/or injury to the leg in the past year, had an intervention for ITB tightness in the past three months, blood flow dysfunctions, hemorrhagic disorders, cancer, or a possibility of pregnancy.^{14,16}

Instrumentation

Biomagnetic Chinese Cupping Therapy Cups (Kangzhu 24-Cup Set, ISO9001 quality certified) were used for the cupping intervention. A set of sham cups were made using the same brand, make, and model of cups, but a hole was created near the top of the cup to reduce the suctioning effect.³⁷ The hole was created by heating a 1mm acupuncture needle and piercing it through the top of the cup.³⁷ A previous study has validated the use of these sham cups.³⁷ Three

pumps were delivered to each cup, regardless if real or sham, on the participant. Baby Oil (Johnson & Johnson) was used as the medium between the skin and the cup for the intervention.

Hip and knee flexion AROM and PROM, as well as the Ober's test were measured with a digital inclinometer (Spitronic, Pro 3600). The clinician established intrarater reliability among repetitions prior to data collection for all dependent variables. $ICC_{3, k/1}$ were above .88.

Procedures

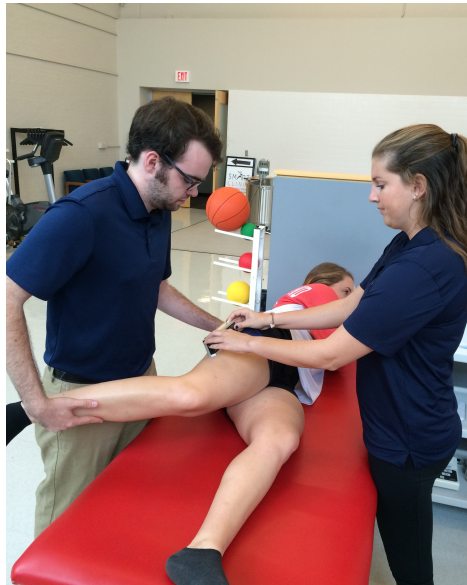When each participant arrived for screening, they were wearing loose fitting athletic shorts that could expose the entire length of the ITB. The participants were informed of the protocol before signing an Institutional Review Board-approved consent form. Anthropometric measurements were then taken for each participant (age, gender, height and mass). To determine if participants were eligible for this study, a research assistant performed an Ober's test on the dominant leg, which was defined as the leg the participant kicked a soccer ball with.

The participant was placed in a side lying position with the pelvis and shoulders aligned along a vertical plane and the knee flexed to 90 degrees.¹³ The research assistant stabilized the pelvis with one hand while the other hand moved the tested limb into hip flexion, abduction, and extension and then lowered the limb into adduction until the descending limb stopped due to either soft tissue restriction or a posterior rotation of the pelvis.¹³ A positive test, measured by a digital inclinometer, was when the descending leg dropped 23.16 degrees or less into adduction.¹³

A digital inclinometer was placed at the midpoint between the anterior superior iliac spine and the patella along the longitudinal axis of the lateral aspect of the thigh.¹³ The clinician placed the digital inclinometer, while the research assistant read and recorded the degree to ensure the clinician was blinded to the measurement. The participants with a negative Ober's test

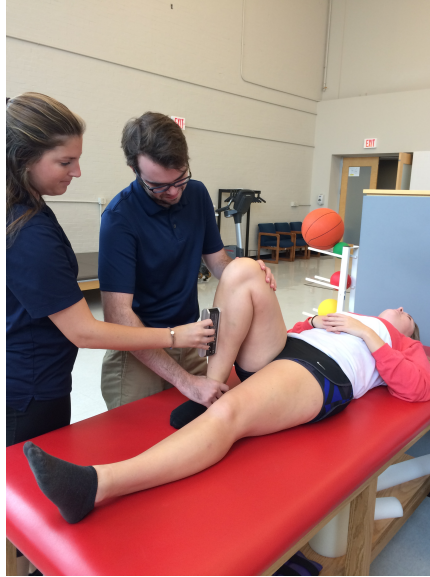
(greater than 23.16 degree leg drop) were thanked for their participation and excluded from this study.

Figure 1. *Ober's test*



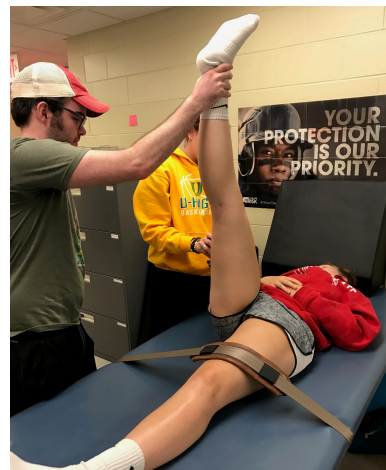The participant then underwent baseline ROM measurements performed by the research assistant in a counterbalanced order. Before each measurement, the digital inclinometer was zeroed on a vertical surface. Knee flexion ROM was measured with the participant in a supine position. The clinician placed a digital inclinometer on the mid-shaft of the tibia. The participant was asked to maximally flex the knee actively. The research assistant recorded the degree of this angle. With the participant in the same starting position and the inclinometer in the same location, the research assistant then passively flexed the knee until the first soft end point was felt. A research assistant recorded the degree of this angle.

Figure 2. *Knee flexion PROM*



Hip flexion ROM was measured with the participant in a supine position. A strap was applied firmly across the contralateral distal thigh to assure minimal pelvic movement.³⁸ With the knee fully extended, the participant actively flexed the hip to its maximal range with instructions to stop when the knee started to bend or when the participant felt as though they could not move any further. A clinician placed the digital inclinometer at the midpoint on the lateral thigh between the greater trochanter and the lateral femoral condyle.³⁸ The research assistant recorded the degree of the reading on the digital inclinometer. The participant then returned to the same starting position (supine, knee extended) and the clinician passively flexed the hip to a point in which a firm end feel was felt.³⁸ The degree on the digital inclinometer was recorded.

Figure 3. *Hip Flexion PROM*



For each measurement the research assistant wrote down the degree angle unbeknownst to the clinician to ensure no bias was present when measuring each participant. Each ROM measurement was taken three times and a mean was used for data analysis.

Next, participants were put into a randomization system and distributed into two groups: dry cupping intervention or sham cupping. The clinician performed the cupping intervention session with the participant in a side lying position on the non-dominant side with the knees slightly bent. A pillow was placed in between the participant's legs for comfort during the intervention. The dry cupping intervention group received four stationary cups during the intervention.²⁰ The placement of the cups was determined by a scanning technique with one cup to target specific adhesions sites on each participant. This scanning was performed by applying one pump to a single cup and moving it along the length of the ITB for 30 seconds. Four stationary cups were then placed on directly on the adhesions that scanning illuminated. These adhesion sites created a catching sensation of the cup as the clinician was scanning the area. Each stationary cup was placed along the ITB between the greater trochanter of the femur and the lateral femoral condyle. Three pumps were delivered to each cup to create a strong suction effect. The intervention session began when the final cup was applied and lasted seven minutes per participant.^{14,20} The participants in the sham cupping group went through the same protocol, but with a set of sham cups. The sham cups provided the same initial suction effect, but the suction dissipated over time.

Immediately after the intervention session, the research assistant performed another Ober's test and took all ROM measurements using the same procedure described previously. Participants were asked to come back 24 hours post intervention for the same measurements to

be taken. The same research assistant measured participants at each time point. The research assistant was blinded to the participant's intervention group.

Data Reduction

All ROM measurements, including Ober's, were noted in Excel and the mean of three trials was used for data analysis. Each individual degree was then adjusted to reflect measures greater or less than 90.

Statistical Analysis

A 2 x 3 mixed model analysis of variance (ANOVA) with one fixed factor at two levels (group: cupping, sham) and one repeated measure at three levels (time: baseline, immediate, 24-hr post) was performed to evaluate the effect of dry cupping versus sham cupping on all outcome variables. Alpha level was set *a priori* at $p \leq 0.05$. All statistical analyses were performed using SPSS (IBM SPSS Statistics for Windows, version 21.0; IBM Corp, Armonk, NY).

CHAPTER IV: RESULTS

Separate repeated measures ANOVAs were performed to compare ROM measures of Ober's test, active and passive hip flexion, and active and passive knee flexion ROM between groups. There were no significant main effects for group or time ($p > .305$). However, after calculating effect sizes between groups for immediate post and 24 hours after intervention, some variables had strong effects outlined in Tables 1-3.

Table 1. *Descriptive statistics on Ober's test.*

Range of Motion	Group	Mean	Standard Deviation	P Value	Effect Size
Baseline Ober's	sham	-13.66	8.07	.216	
	cupping	-11.92	5.45		
Immediate Post Ober's	sham	-12.61	7.45		-.66 (-1.3- -.03)
	cupping	-16.92	5.26		
24 Hours Post Ober's	sham	-13.95	5.86		-.67 (-1.3- -.03)
	cupping	-17.45	4.48		

Table 2. *Descriptive statistics on hip flexion ranges of motion.*

Range of Motion	Group	Mean	Standard Deviation	P Value	Effect Size
Baseline Hip Flex AROM	sham	90.19	13.49	.305	
	cupping	91.22	10.20		
Immediate Post Hip Flex AROM	sham	92.27	13.15		.12 (-.5-.74)
	cupping	93.73	10.64		
24 Hours Post Hip Flex AROM	sham	90.06	12.99		.67 (.03-1.3)
	cupping	97.05	7.19		
Baseline Hip Flex PROM	sham	93.23	13.08	.365	
	cupping	93.09	11.05		
Immediate Post Hip Flex PROM	sham	92.97	13.64		.03 (-.59-.65)
	cupping	93.39	11.77		
24 Hours Post Hip Flex PROM	sham	89.48	13.52		.66 (.02-1.29)
	cupping	97.03	8.79		

Table 3. Descriptive statistics on knee flexion ranges of motion.

Range of Motion	Group	Mean	Standard Deviation	P Value	Effect Size	
Baseline Knee Flex AROM	sham	98.33	4.98	.394		
	cupping	98.37	4.06			
Immediate Post Knee Flex AROM	sham	99.54	5.31		.394	-.28 (-.90-.34)
	cupping	98.30	2.86			
24 Hours Post Knee Flex AROM	sham	100.35	5.80			.394
	cupping	98.30	4.27			
Baseline Hip Knee PROM	sham	101.62	4.20	.496		
	cupping	100.62	4.30			
Immediate Post Knee Flex PROM	sham	101.65	3.54		.496	-.03 (-.65-.59)
	cupping	101.52	4.08			
24 Hours Post Knee Flex PROM	sham	102.36	5.66			.496
	cupping	101.21	4.08			

CHAPTER V: DISCUSSION

ITB tightness is important to address as it is commonly found in the active population.^{1,12} When existing fascial adhesions lead to an overall tightness of the fascia, pulling or overcrowding of the ITB fibers can occur and lead to altered biomechanics which increase the risk of injury.²⁴ Due to the lateral patellar insertion, ITB tightness can result in a lateral pull of the patella leading to patellofemoral dysfunction and ITB friction syndrome.^{6,7,9,22} ITB tightness can also cause an anterior pull on the tibia, at the ITB attachment site of Gerdy's tubercle, and increase the risk of ACL injuries.^{5,10-12} The anatomy and physiology of the ITB suggests that it is not a structure that can be stretched and physiological lengthening if the fascia is limited.^{9,25,26} Previous studies conducted on stretching and manual therapy on the ITB have found that there is not enough mechanical stress on the fascia to elicit an actual deformation and elongation of the tissue.^{26,27} Therefore, other therapies need to be introduced to address and treat ITB tightness.

To the best of our knowledge this is the first study that investigated the effects of dry cupping on ITB tightness. Although we did not observe statistically significant p-values, strong effect sizes for certain measures were found. Both active and passive hip flexion had improvements in ROM with strong effect sizes between groups 24-hours post treatment, indicating potential clinical meaningfulness. Moreover, a strong effect size was observed for improved Ober's test (less restriction) between groups immediately post intervention and 24-hours post intervention. Knee flexion ranges of motion saw no changes throughout the duration of the study. These strong effect sizes indicate clinical meaningfulness. As a clinician, a five to six degree change in an Ober's test is meaningful enough to use dry cupping as a treatment option to combat ITB tightness. Likewise, a five to six degree increase in active hip flexion

ROM is a significant enough change for clinicians to see cupping as an effective treatment option.

The positive changes in measurements indicate a single cupping intervention session increases hip flexion ranges of motion and leads to a relief in tightness of the ITB, with the changes being meaningful to a clinician. The results of this study support those of other research studies in which cupping has resulted in an increase of ranges of motion and decrease of tightness.¹⁵⁻¹⁹ There is no proven physiological mechanism for the effectiveness of cupping. One commonly inferred theory of cupping is the result of increasing blood flow to an area assisting in the healing process.^{15-18,20,36} The tensile stress created from the suctioning of the skin is thought to be enough to rupture blood vessels and increase blood flow.³³ Another proposed theory states that cupping releases chemical transmitters to block pain messages and activate the gate control theory of pain. This is theorized to occur from the vasoconstriction/dilation occurring under the surface of the cup.²⁰

The researchers have attributed the lack of increase of knee flexion to the positioning of the participant when performing knee flexion; the gastrocnemius would come into contact with posterior thigh limiting the amount of knee flexion to be obtained. Deficits in knee flexion were also not observed, creating a ceiling effect for the measurement, where there was no room from improvement even if the treatment was effective.

As with any research, this study has limitations. The small sample size utilized in this study may have played a role in the lack of statistically significant p-values. If the number of participants was larger the standard deviations may have been smaller leading to more statistical significance. However, the strong effects sizes did indicate clinical meaningfulness for dry cupping on ITB tightness. Another limitation in this study was the lack of multiple ranges of

motion deficits for inclusion criteria. Had the researchers included hip and knee flexion deficits in the inclusion criteria there may have been more evident increases in these ranges of motions after the cupping intervention.

Future research should aim to standardize dry cupping intervention sessions. The researchers chose the dry cupping guidelines based off the limited research available and past clinical experience with the intervention. As of now, there are no specific guidelines to a cupping intervention; everything from treatment time to the placement of cups varies. Research focusing on standardizing a cupping intervention session could improve future research and utilization of dry cupping in the clinical setting. Research on dry cupping should continue to be able to suggest a mechanism for the effectiveness of this therapy. Existing hypotheses on the physiological mechanism should be investigated. Additionally, research should evaluate the duration of the effects seen from a single cupping intervention session. The positive effects on tightness and ranges of motion observed after 24 hours may have just been the beginning stages of the relief on ITB tightness. Perhaps more significant changes could have been seen after a greater lapse of time post intervention. Lastly, future research on dry cupping should aim to include the use of subjective measures as outcome variables. Participants in the experimental group reported feelings of increased flexibility and analyzing those findings may have further supported the effectiveness of dry cupping.

In conclusion, our findings indicate that a single intervention of dry cupping is probably effective in reducing ITB tightness and increasing hip flexion ranges of motion. These changes can be observed 24 hours post intervention in addition to immediately after the intervention. Further studies are needed to confirm these results and to further evaluate the effectiveness of

dry cupping. However, this study supports the assumption that dry cupping may be a safe and effective treatment option to combat ITB tightness seen by clinicians.

REFERENCES

1. Gose JC, Schweizer P. Iliotibial band tightness. *J Orthop Sports Phys Ther.* 1989;10(10):399-407.
2. Marieb E, N., Hoehn K. *Human Anatomy & Physiology.* Tenth ed. Prentice Hall, Inc.2016.
3. Simmonds N, Miller P, Gemmell H. A theoretical framework for the role of fascia in manual therapy. *J Bodyw Mov Ther.* 2012;16(1):83-93.
4. Tozzi P. Selected Fascial Aspects of Osteopathic Practice. *Journal of Bodywork and Movement Therapies.* 2012;16:22.
5. Hudson Z, Darthuy E. Iliotibial band tightness and patellofemoral pain syndrome: a case-control study. *Man Ther.* 2009;14(2):147-151.
6. Beals RK. The Iliotibial Tract: A review. *Current Orthopaedic Practice.* 2009;20(1):5.
7. Vieira EL, Vieira EA, da Silva RT, Berlfein PA, Abdalla RJ, Cohen M. An anatomic study of the iliotibial tract. *Arthroscopy.* 2007;23(3):269-274.
8. Krivickas LS, Feinberg JH. Lower extremity injuries in college athletes: relation between ligamentous laxity and lower extremity muscle tightness. *Arch Phys Med Rehabil.* 1996;77(11):1139-1143.
9. Fairclough J, Hayashi K, Toumi H, et al. The functional anatomy of the iliotibial band during flexion and extension of the knee: implications for understanding iliotibial band syndrome. *J Anat.* 2006;208(3):309-316.
10. Herrington L, Rivett N, Munro S. The relationship between patella position and length of the iliotibial band as assessed using Ober's test. *Man Ther.* 2006;11(3):182-186.
11. Puniello MS. Iliotibial band tightness and medial patellar glide in patients with patellofemoral dysfunction. *J Orthop Sports Phys Ther.* 1993;17(3):144-148.
12. Khaund R, Flynn SH. Iliotibial band syndrome: a common source of knee pain. *Am Fam Physician.* 2005;71(8):1545-1550.
13. Ferber R, Kendall KD, McElroy L. Normative and critical criteria for iliotibial band and iliopsoas muscle flexibility. *J Athl Train.* 2010;45(4):344-348.
14. Mehta P, Dhapte V. Cupping therapy: A prudent remedy for a plethora of medical ailments. *J Tradit Complement Med.* 2015;5(3):127-134.
15. Kim TH, Kang JW, Kim KH, et al. Cupping for treating neck pain in video display terminal (VDT) users: a randomized controlled pilot trial. *J Occup Health.* 2012;54(6):416-426.
16. Lauche R, Cramer H, Choi KE, et al. The influence of a series of five dry cupping treatments on pain and mechanical thresholds in patients with chronic non-specific neck pain--a randomised controlled pilot study. *BMC Complement Altern Med.* 2011;11:63.
17. Teut M, Kaiser S, Ortiz M, et al. Pulsatile dry cupping in patients with osteoarthritis of the knee - a randomized controlled exploratory trial. *BMC Complement Altern Med.* 2012;12:184.
18. Akbarzadeh M, Ghaemmaghami M, Yazdanpanahi Z, Zare N, Azizi A, Mohagheghzadeh A. The Effect Dry Cupping Therapy at Acupoint BL23 on the Intensity of Postpartum Low Back Pain in Primiparous Women Based on Two Types of Questionnaires, 2012; A Randomized Clinical Trial. *Int J Community Based Nurs Midwifery.* 2014;2(2):112-120.
19. Markowski A, Sanford S, Pikowski J, Fauvell D, Cimino D, Caplan S. A pilot study analyzing the effects of Chinese cupping as an adjunct treatment for patients with

- subacute low back pain on relieving pain, improving range of motion, and improving function. *J Altern Complement Med.* 2014;20(2):113-117.
20. Rozenfeld E, Kalichman L. New is the well-forgotten old: The use of dry cupping in musculoskeletal medicine. *J Bodyw Mov Ther.* 2016;20(1):173-178.
 21. Schleip R, Jäger H, Klingler W. What is 'fascia'? A review of different nomenclatures. *J Bodyw Mov Ther.* 2012;16(4):496-502.
 22. Starkey C, Brown S, Ryan J. *Examination of Orthopedic and Athletic Injuries.* 3 ed. Philadelphia, PA: F.A. Davis Company; 2010.
 23. Schleip R. Fascial Plasticity - A New Neurobiological Explanation: Part 1. *Journal of Bodywork and Movement Therapies.* 2003;7(1):9.
 24. Barnes M. The Basic Science of Myofascial Release: Morphologic Changes in Connective Tissue. *Journal of Bodywork and Movement Therapies.* 1997;1(4):8.
 25. Fairclough J, Hayashi K, Toumi H, et al. Is iliotibial band syndrome really a friction syndrome? *J Sci Med Sport.* 2007;10(2):74-76; discussion 77-78.
 26. Falvey EC, Clark RA, Franklyn-Miller A, Bryant AL, Briggs C, McCrory PR. Iliotibial band syndrome: an examination of the evidence behind a number of treatment options. *Scand J Med Sci Sports.* 2010;20(4):580-587.
 27. Chaudhry H, Schleip R, Ji Z, Bukiet B, Maney M, Findley T. Three-dimensional mathematical model for deformation of human fasciae in manual therapy. *J Am Osteopath Assoc.* 2008;108(8):379-390.
 28. Threlkeld AJ. The effects of manual therapy on connective tissue. *Phys Ther.* 1992;72(12):893-902.
 29. Bialosky JE, Bishop MD, Price DD, Robinson ME, George SZ. The mechanisms of manual therapy in the treatment of musculoskeletal pain: a comprehensive model. *Man Ther.* 2009;14(5):531-538.
 30. Schleip R. Fascial Plasticity - A New Neurobiological Explanation: Part 2. *Journal of Bodywork and Movement Therapies.* 2003;7(2):13.
 31. Ramsey SM. Holistic manual therapy techniques. *Prim Care.* 1997;24(4):759-786.
 32. Nickel JC. Management of urinary tract infections: historical perspective and current strategies: Part 2--Modern management. *J Urol.* 2005;173(1):27-32.
 33. Tham LM, Lee HP, Lu C. Cupping: from a biomechanical perspective. *J Biomech.* 2006;39(12):2183-2193.
 34. Cramer H, Lauche R, Hohmann C, et al. Randomized controlled trial of pulsating cupping (pneumatic pulsation therapy) for chronic neck pain. *Forsch Komplementmed.* 2011;18(6):327-334.
 35. Kim JI, Kim TH, Lee MS, et al. Evaluation of wet-cupping therapy for persistent non-specific low back pain: a randomised, waiting-list controlled, open-label, parallel-group pilot trial. *Trials.* 2011;12:146.
 36. Kim JI, Lee MS, Lee DH, Boddy K, Ernst E. Cupping for treating pain: a systematic review. *Evid Based Complement Alternat Med.* 2011;2011:467014.
 37. Lee MS, Kim JI, Kong JC, Lee DH, Shin BC. Developing and validating a sham cupping device. *Acupunct Med.* 2010;28(4):200-204.
 38. Pua YH, Wrigley TV, Wrigley TW, Cowan SM, Bennell KL. Intrarater test-retest reliability of hip range of motion and hip muscle strength measurements in persons with hip osteoarthritis. *Arch Phys Med Rehabil.* 2008;89(6):1146-1154.